

Use of a Clear Absorbent Acrylic Dressing for Debridement

by

Deb Schimmelpfenning, RN, BSN, CWCN, CNS

Sharon Mollenhauer, RN, BSN, CWCN, CNS

Use of a Clear Absorbent Acrylic Dressing for Debridement

by Deb Schimmelpfenning, RN, BSN, CWCN, CNS and Sharon Mollenhauer, RN, BSN, CWCN, CNS

Problem Statement

Outpatient wound care centers are often challenged with patients whose wounds have multiple etiologies. These patients require a plan of care that addresses all underlying factors as well as wound management to debride devitalized tissue and promote healing. Clinicians practicing in outpatient wound care clinics must appreciate the unique challenges for wound management required by the home health care setting.^{1,2} The current economic environment requires a home care agency to optimize nursing visits to achieve financial as well as clinical outcomes. This requires dressing materials that facilitate healing, allow for long wear and are easy for clinicians or caregivers to use. While hydrocolloid dressings are widely used for management of partial thickness ulcers, some formulations and designs have drawbacks that limit their usefulness for home care patients. Limited ability to manage wound drainage can result in loss of dressing integrity or “dressing breakdown” in the wound. Dressing profile and design of dressing edge often contributes to dressing failure. The edges of a dressing can catch on linens or clothing causing them to curl and roll off the wound site. This can also be a source of superficial injury to the surrounding skin.

In addition to the potential impact on clinical outcomes, dressing failure can add unwanted cost. Labor remains the single biggest expense to a home health agency. When a patient is not capable of self care or a caregiver is not available, unscheduled dressing changes requiring additional nursing visits can be a significant financial problem.

We were interested in evaluating a new clear absorbent acrylic wound care dressing. This dressing incorporates an absorbent pad encased between two layers of transparent film dressing. The pad is composed of a unique acrylic polymer that remains clear as it absorbs exudate. This allows the wound or drainage to be observed without removing the dressing. The transparent film extends beyond the edges of the pad helping to keep the edges in place during wear. The upper layer of film is coated with a slippery material to reduce friction.

Objectives for dressing evaluation:

1. Identify wounds suitable for debridement with a clear absorbent acrylic dressing.
2. Identify the benefits of the clear absorbent acrylic dressing compared to a traditional hydrocolloid.
3. Understand suitability of using a clear absorbent acrylic dressing for care of partial thickness wounds.

Our case study involved a thirty-one-year-old paraplegic male with a medical history including controlled, insulin dependent diabetes. He presented with a one month old burn on his right greater trochanter secondary to prolonged exposure to a heating pad. Upon admission to the wound clinic at Proctor Hospital (1/27/04) his chronic wound measured 5.4 cm x 3.9 cm with an adjacent smaller wound of 0.6 cm x 0.4 cm. (Figure 1) The wounds were 80% tenacious slough and softening eschar. The wounds showed no symptoms of infection. He was treated with silver sulfadiazine cream by his family physician. The patient reported that he did not have a pressure reducing sleep surface, however he was using a Jay II wheelchair cushion.

The traditional approach of using topical antimicrobials for minor partial-thickness burns has recently been questioned.³ The appearance of the wound as well as the practical considerations for topical therapy in the home environment led us to search for an alternative dressing.

Goals identified:

1. Provide pressure relief.
2. Facilitate debridement and promote healing.
3. Facilitate wound management within the home setting.
4. Improve self-care to prevent skin damage in future.

Methodology

1. Implement the use of a pressure reducing mattress overlay.
2. Provide a dressing that promotes autolytic debridement with minimal dressing changes and allows for usual hygiene habits.
3. Reinforce teaching about the etiology of skin damage including pressure.
4. Develop a tool to compare the features of the clear absorbent acrylic dressing with a traditional hydrocolloid dressing.

To determine whether this product would be useful in our practice and more specifically in the home health setting, we developed a table (see Table 1) that incorporated important criteria for dressing selection. This enabled us to compare the new dressing to our existing hydrocolloid dressing in a systematic fashion.

Table 1. Bold text indicates criteria where the clear absorbent acrylic dressing provided a significant advantage.

Characteristics	3M™ Tegaderm™ Absorbent Clear Acrylic Dressing	Hydrocolloid Dressing*
Odor	No	Yes
Easy Application	Yes	Yes
Wound Visibility	Yes	No
Dressing Breakdown	No	Yes
Rolling Edges	No	Yes
Absorbent	Yes>	Yes
Extended Wear Time	Yes	Yes
Debridement	Yes	Yes
Waterproof	Yes	Yes
Reduce Friction	Yes	Yes
Contaminant Barrier	Yes	Yes

Treatment Plan

Pressure relief was accomplished with the use of a static air mattress overlay. Using the patient education publication “Treating Pressure Sores”⁴, the patient was taught the effects of pressure and the ways in which this can be managed in his home. The clear absorbent acrylic dressing in the 11.4 cm x 12.7 cm size (See Figures 2 and 6) was chosen with expectations to provide autolytic debridement, greater absorption of drainage, visual assessment, ease of application, the ability to continue daily showers and to facilitate transfers. Dressing changes were scheduled two times a week in the clinic initially, with intention to extend wear time to weekly as autolysis occurred and drainage

decreased. The wound was cleansed with a mild wound cleanser and a liquid skin barrier applied to surrounding skin. The patient continued his usual showering and transfers without the dressing rolling or becoming dislodged. Against our advice, he continued use of his hot tub. No ill effects were noted on return to the clinic. The unpleasant odor typically associated with hydrocolloid use was absent at the time of dressing change. The clear absorbent acrylic dressing promoted softening of slough to facilitate debridement. Buds of granulation tissue were noted on the first dressing change (See Figure 3) with improvement continuing at a subsequent visit on 2/18/04 (See Figure 4). Wound measurements were reduced to 1.4 cm x 1.3 cm at the close of the study on 4/27/04. (See Figure 5). Though significant improvement occurred during the study, we believe healing results were delayed due to patient’s poor compliance with pressure relief and inability to keep scheduled appointments.

Conclusion

The clear absorbent acrylic dressing:

1. accomplished autolytic debridement.
2. was easily used in the home care environment requiring only one or two dressing changes per week.
3. remained in place and promoted significant improvement despite poor patient compliance.
4. was easily applied and removed.
5. maintained the integrity of the surrounding skin.
6. reduced friction and shear.
7. provided visual access to the wound.

* Convatec DuoDERM® Signal™

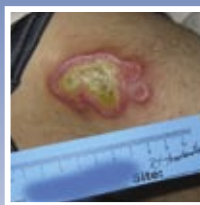

Figure 1
Initial assessment
1/27/04

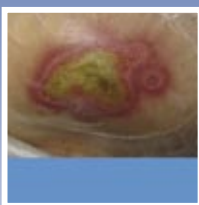


Figure 2
Application of clear
absorbent acrylic
dressing upon
initial visit

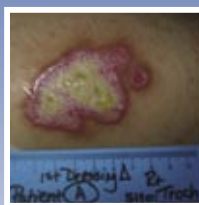

Figure 3
First dressing change
demonstrating
autolytic
debridement

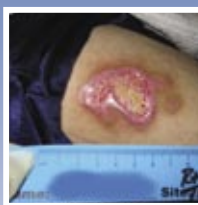

Figure 4
Assessment on
2/18/04

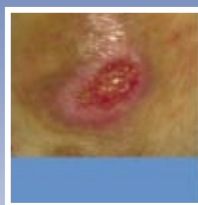

Figure 5
Final assessment
with closure of study



Figure 6

References

1. Ovington, L., Pierce, B. Wound dressings: form, function, feasibility, and facts. In: Krasner, DL, Rodeheaver, GT, Sibbald, RG (eds). *Chronic Wound Care: A Clinical Source Book for Healthcare Professionals*, Wayne, PA. HMP Communications, 2001:311–319.
2. Ovington, LG. Wound Care Products: How to Choose. *Home Healthcare Nurse*. 19 (4), 224–232.
3. Helvig, EI. Managing Thermal Injuries Within WOCN Practice. *JWOCN*. 29 (2).
4. AHCPR Publication No. 95-0654. Consumer Version Clinical Practice Guideline Number 15. *Treating Pressure Sores*. December 1994.

DuoDERM® Signal™ is a registered trademark of Convatec, a Bristol-Meyers Squibb Company.



Health Care

3M Center, Building 275-4W-02
St. Paul, MN 55144-1000
USA
1 800 228-3957
www.3M.com/healthcare

3M Canada

Post Office Box 5757
London, Ontario N6A 4T1
Canada
1 800 563-2921



*Minimum 10%
Post-Consumer Fiber*

Printed in U.S.A.
© 3M 2005 All Rights Reserved
70-2009-7063-3