

InterDry® Case Studies

InterDry®



The challenges of skin fold management

Intertriginous dermatitis (intertrigo) is a common inflammatory skin condition. Skin-to-skin or skin-to-device contact may cause friction and can hold moisture against the skin's surface. This puts patients at risk for skin complications such as maceration, erythema, erosion, itching/burning, odor and pain.

Current treatments attempt to manage the symptoms but do not solve the underlying cause. The 2013

International Consensus Panel for Intertrigo¹ agreed powders such as cornstarch may encourage fungal growth and have no proven benefit. Linen, gauze and paper towels placed between skin folds are usually ineffective. These textiles absorb moisture; however, they do not allow the moisture to evaporate, thereby promoting skin damage. As a result, resolution is often not achieved and symptoms persist leading to more serious complications.²

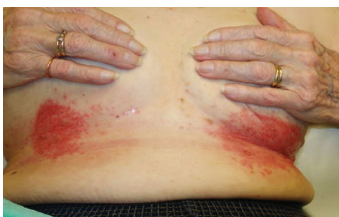


FIGURE 1³
Candidal intertrigo beneath both breasts at initial visit.

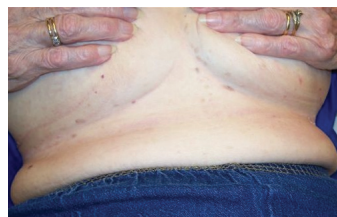

FIGURE 2³
Week 3 resolution of candidal intertrigo beneath both breasts.

Manage the cause, not only the symptoms

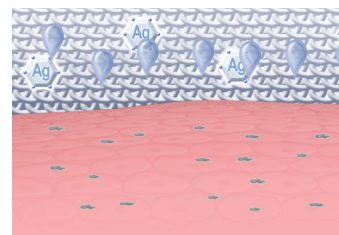
By addressing the causes of skin fold maladies, InterDry[®] moisture-wicking fabric with antimicrobial silver is the first effective solution for managing complications associated with skin folds.



MOISTURE
The soft, knitted 100% polyester fabric wicks and translocates excess moisture, keeping the skin dry.



FRICTION
The polyurethane coating reduces friction in skin folds.



FUNGAL & BACTERIAL ORGANISMS
Ionic silver provides effective broad-spectrum antimicrobial action within the fabric for up to 5 days.

References

1. Sibbald RG, Kelly J, Kennedy-Evans KL, Labrecque C, Waters N. A practical approach to the prevention and management of intertrigo, or moisture-associated skin damage, due to perspiration: expert consensus on best practice. *Wound Care Canada - Supplement*. 2013;11(2):1-21
2. Black JM, Gray M, Bliss DZ, Kennedy Evans KL, Logan S, Baharestani M, Colwell JC, Goldberg M, Ratcliff CR. MASD part 2: incontinence-associated dermatitis and intertriginous dermatitis: a consensus. *J Wound Ostomy Continence Nurs*. 2011;38(4):359-70
3. Vorbeck E. Evaluation of a skin fold management textile with antimicrobial silver in a variety of clinical situations. Unpublished case studies. 2007

InterDry[®] improves clinical outcomes

Kennedy-Evans and colleagues¹ performed a clinical study to determine the efficacy of the moisture-wicking fabric with silver in place of standard treatments. Twenty-one (21) subjects with intertriginous dermatitis from two long-term care centers were enrolled in the study.

Reduction in itching/burning: Fifteen (15) subjects had itching/burning on Day 1. On Day 5, zero (0) subjects had itching/burning. There was a statistically significant reduction in itching/burning ($P = .0001$) by Day 3 and ($P < .0001$) by Day 5.

Reduction in maceration: Ten (10) subjects had maceration on Day 1. One (1) subject had maceration on Day 3 and Day 5 resulting from textile becoming soiled with urine and not removed immediately.

Reduction in denudement: Seven (7) subjects had denudement on Day 1. On Day 5, two (2) subjects had denudement that was improving. There was a significant reduction on Day 3 ($P = .125$) and on Day 5 ($P = .062$).

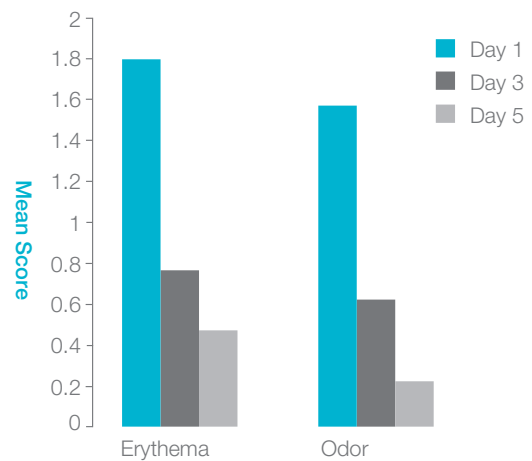
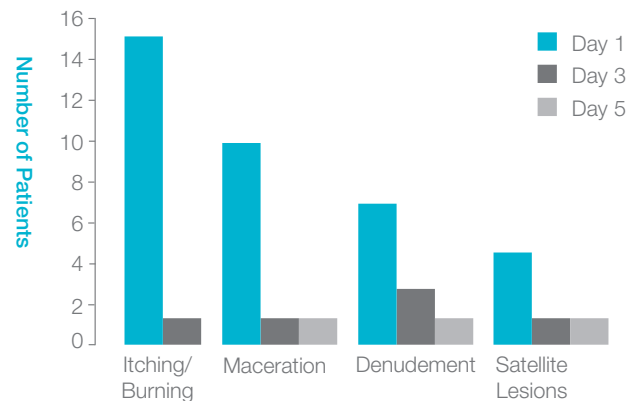
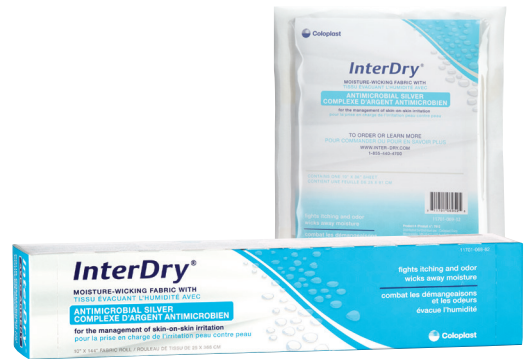Reduction in satellite lesions: Five (5) subjects had satellite lesions on Day 1. On Day 3 and Day 5, one (1) subject had satellite lesions that were improving.

Reduction in erythema: All of the subjects (21) entered the study with erythema. There was a statistically significant reduction in erythema ($P < .0001$) by Day 3 and Day 5.

Reduction in odor

Separated odor: Twelve (12) subjects had odor on Day 1. There was a statistically significant reduction in separated odor ($P = .0020$) by Day 3 and ($P = .0034$) by Day 5. Two (2) subjects with odor on Day 5 had improved significantly from Day 1. *Note: One (1) subject had no odor on Day 1 and Day 3 and minimal odor (scarcely noticeable) on Day 5 due to the textile being soiled with urine and left in place.*

Closed odor: Closed odor was not statistically analyzed. One (1) subject had closed odor on Day 1. On Day 3 and Day 5, zero (0) subjects had closed odor.



References

1. Kennedy-Evans KL, Viggiano B, Henn T, Smith D. Multi-site feasibility study using a new textile with silver for management of skin conditions located in skin folds. Poster presented at: 20th Annual Symposium on Advanced Wound Care; April 28 - May 1, 2007; Tampa, FL and 39th WOCN[®] Society Annual Conference; June 9-13, 2007; Salt Lake City, UT

Introduction to skin fold management

Author: Susan Gallagher, PhD, MSN, MA, RN, CBN, HCRM, CSPHP

Sponsored by Coloplast

Historical challenges

Over the past few decades healthcare providers have struggled to address issues of skin fold management.

Powders and creams have been the mainstay of treatment. More creative processes have included taping skin folds apart or placing flannel or cotton fabric between skin folds to discourage skin-to-skin contact. Resolution of skin injury may be achieved; however, the process has been time consuming and costly. Historically, a solution to skin fold management had been elusive.

Special patient populations

From a clinical perspective, excess moisture often leads to intertriginous dermatitis (ITD), especially in the presence of deep cutaneous folds. Obesity is thought to be a primary factor in the development of ITD because the presence of skin folds places the patient at greater risk for prolonged skin-to-skin contact. ITD often occurs among adults, children or infants who are obese or who have a weight maldistribution. Inflammation may develop under or within abdominal folds, in neck creases, or in popliteal or antecubital fossae. However, a number of different types of individuals can develop this condition. For example, in addition to obesity, risk factors for ITD include: hyperhidrosis; systemic infection; chronic steroid and

antibiotic use; immunosuppression; immobility; and diabetes, especially in the presence of excess moisture.

Most agree a gender or ethnic/racial component doesn't exist; however, age may be a factor. The very old and very young typically are affected more often because of reduced immunity, immobilization, and moisture. Further, in the aging population, age-related tissue loss is associated with ITD. For instance, as the mandible shrinks in elderly persons and the vertical dimensions decrease around the mouth, inflammation and ITD can occur under and within the accentuated nasolabial folds. ITD manifests in a number of areas over the aging body. Digital ITD is not uncommon among individuals who have contractures due to stroke or any other condition that impairs use of the hands and fingers. Any area of the body where there is prolonged skin-to-skin contact is vulnerable. All risk factors are aggravated by hot and humid conditions. Thus a regional factor exists as well as a patient population component.

Unfortunately, the true prevalence of ITD is unknown in a general sense, research suggests that the issue is pervasive among certain populations, and affected individuals do not always seek medical treatment. For

example, McMahon and others reported that in a survey of 1116 hospitalized female patients 11.2% had active or resolved inframammary lesions. Researchers found the prevalence was higher among elderly individuals or those with mental illness. Mathur and others describe a higher rate of ITD among obese adolescents. Although the numbers of critically ill patients who experience ITD is not clear, anecdotally, providers understand this is a high-risk group for several reasons. For instance, in the intensive care areas patients generally experience an increased exposure to moisture due to increased perspiration associated with illness/diseases, fever or medications. There is more opportunity for skin-to-skin contact while in the lying position and an increase in skin friction with movement in bed or perhaps restriction of movement because of hemodynamic instability or reluctance to move a complex, critically ill individual.

Clinical and economic concerns

Some experts contend that prevention is a more appropriate alternative to treatment and recommend a number of preventive strategies. For example, patients are advised to control blood sugar, use cotton undergarments, lose weight, avoid tight clothing and avoid

unnecessary antibiotic or steroid use. Experts suggest keeping the area dry and exposed to the air as much as possible to prevent recurrences.

As indicated in the McMahon study, many individuals have resolution of the ITD once their general conditions

improve. However, recurrence of ITD is common. Recurrences lead to direct and indirect costs. Indirect costs include time from work, home and family; travel time to providers; embarrassment from odor; threats to productivity due to discomfort; frustration and more. Direct costs

might include dressings, antibiotics, laboratory studies, home health or acute care expenses not covered by the patient's insurance carrier and more. Skin fold management has become an ongoing struggle for many individuals from a humanistic, clinical and economic perspective.

References

1. Del Rosso JQ, Draelos ZD, Jorizzo JL, Joseph WS, Ribotsky BM, Rich P. Modern methods to treat superficial fungal disease. *Cutis*. 2007;79(2 suppl):6-29
2. Guitart J, Woodley DT. Intertrigo: a practical approach. *Compr Ther*. 1994;20(7):402-409
3. Scott TD. Intertrigo. *J Dermatol Nurses Assoc*. 2010;2(5):226
4. Mistiaen P, Poot E, Hickox S, Jochems C, Wagner C. Preventing and treating intertrigo in the large skin folds of adults: a literature overview. *Dermatol Nurs*. 2004;16(1):43-56
5. Vanhootehem O, Szepietuk G, Paurobally D, Heureux F. Chronic interdigital dermatophytic infection: a common lesion associated with potentially severe consequences. *Diabetes Res Clin Pract*. 2011;91(1):23-5
6. McMahon R. The prevalence of skin problems beneath the breasts of in-patients. *Nurs Times*. 1991;87(39):48-51
7. Mathur AN, Goebel L. Skin findings associated with obesity. *Adolesc Med State Art Rev*. 2011;22(1):146-56

InterDry[®] reduces treatment time and cost

Cost-effective treatment of intertrigo¹

A comparison of potential retail costs (Canadian Dollar, C\$) for each treatment and potential nursing time are listed. In general this type of treatment may be offered in chronic care institutions, but it is unlikely that twice daily nursing visits would be authorized through home care.

*Retail cost in Canadian Dollars (C\$); institutional cost lower. Source: Retail pharmacy costs

Agent	Associated costs
Clotrimazole antifungal cream, 30g, twice daily for 2 weeks, 7.5 applications per tube	
Cost per tube	C\$12.99
Cost per day	C\$3.46
Cost for 2 weeks treatment with clotrimazole	C\$48.44
Nursing time	28 apps over 14 days
Nystatin antifungal cream, 30g, twice daily for 2 weeks, 7.5 applications per tube	
Cost per tube	C\$4.99
Cost per day	C\$1.33
Cost for 2 weeks treatment with nystatin	C\$18.63
Nursing time	28 apps over 14 days
Moisture-wicking fabric with silver , 10"x12", applied every 5 days	
Cost per roll 10"x12'*	C\$107.64
Cost per day	C\$1.78
Resolution in 5 days with the moisture-wicking fabric with silver	C\$8.97
Nursing time	5 visits
Resolution in 10 days with the moisture-wicking fabric with silver	C\$17.94
Nursing time	10 visits

References

1. Sibbald RG, Kelly J, Kennedy-Evans KL, Labrecque C, Waters N. A practical approach to the prevention and management of intertrigo, or moisture-associated skin damage, due to perspiration: expert consensus on best practice. *Wound Care Canada - Supplement*. 2013;11(2):1-21

When ITD hits home: best practice tips for using a moisture-wicking fabric with silver for intertriginous dermatitis

Author: Patti Haberer, MA, BSN, RN, CWOCN and Clinical Consultant for Coloplast Corp

Presented at the 7th Annual Symposium on Advanced Wound Care, September 2015

Presented at the Southeast Region of the WOCN® Society Annual Conference, September 2015

Sponsored by Coloplast

Introduction

Intertriginous dermatitis (ITD), also known as intertrigo, is one of the four most common forms of moisture-associated skin damage.¹ ITD is defined as inflammation resulting from moisture trapped in skin folds subject to friction.² Symptoms include erythema, inflammation, maceration, erosion/denudation, odor and pain of the skin inside and adjacent to skin folds.^{1,2,3} Major risk factors include hyperhidrosis; obesity, especially with pendulous breasts; deep skin folds; immobility and diabetes mellitus.² All risk factors are exacerbated by hot, humid conditions.² The most common fungal organism in ITD is *Candida*.³ However, a recent study found *Candida* is not the most prevalent organism found in skin folds.⁴ Standard treatments often used for ITD, such as drying agents, barrier creams, topical antifungals and absorptive materials, may be

ineffective in some patients.²

Moisture-wicking fabric with silver has been shown to relieve the signs and symptoms of ITD within a five-day period.⁵

Purpose

The objective of this case study was to share best practice tips using a moisture-wicking fabric with antimicrobial silver.

Case Discussion

After residing in an assisted living facility in Texas for two years, it was time to move my 80-year-old family member closer to me. She traveled with my husband and I on a two day, 1000 mile road trip to her new home in Florida. Her medical history includes obesity (5'3", 172 pounds, BMI 30.5), bilateral mastectomy, uncontrolled diabetes, hypertension, hyperlipidemia, and dementia. Following her first morning shower,

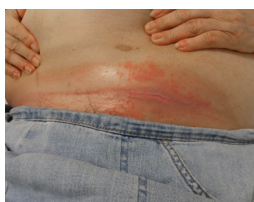I noticed a mild case of ITD (erythema and pain) within her right axilla. This necessitated a further assessment of all skin folds. Under her large pannus revealed a severe case of ITD (erythema, maceration, satellite lesions, denuded skin at the base of the fold, odor and pain). A moisture-wicking fabric with silver was applied to both areas to manage the complications associated with skin folds: moisture, friction and fungal/bacterial organisms.

Conclusion

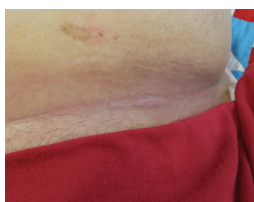The moisture-wicking fabric with antimicrobial silver quickly and effectively resolved both cases of intertriginous dermatitis (ITD).

- At Day 2 the erythema and pain in the axilla was 100% resolved
- At Day 5 the erythema, satellite lesions, odor, denuded area and pain under the pannus was 100% resolved

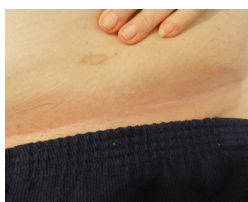RESULTS: PANNUS



Day 1: Severe case of ITD (erythema, maceration, satellite lesions, denuded skin at the base of the fold, odor and pain).

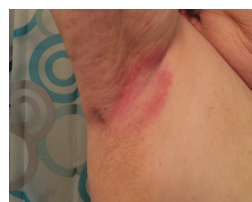

Day 3: Erythema, maceration, satellite lesions and odor had resolved. Denuded area partially resolved.

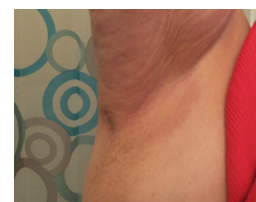

Day 5: 100% resolved.

RESULTS: AXILLA

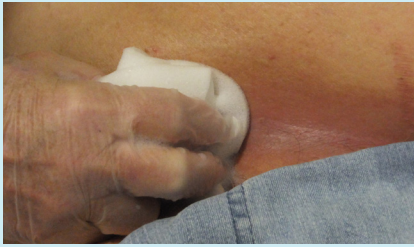

Day 1: Mild case of ITD (erythema and pain).



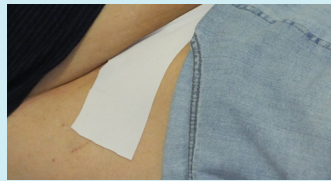
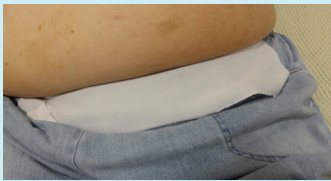Day 2: Erythema and pain had resolved.

Best practice tips



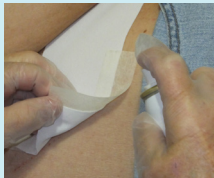
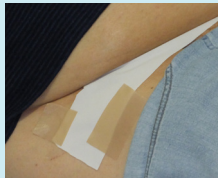
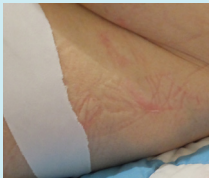PREVENT FURTHER TRAUMA

Clean the painful denuded areas with a no-rinse, self-sudsing disposable washcloth to prevent further trauma. Carefully dry with a soft towel.



PREVENT DISLODgement DURING ROUTINE ACTIVITIES OF DAILY LIVING

The moisture-wicking fabric was originally positioned to allow 2" plus to hang below the pannus. During toileting the moisture-wicking fabric was inadvertently removed. Moisture-wicking fabric was repositioned to allow 2" plus to be exposed on either side of the pannus.



SECURE WITHOUT CAUSING FURTHER TRAUMA TO THE SKIN

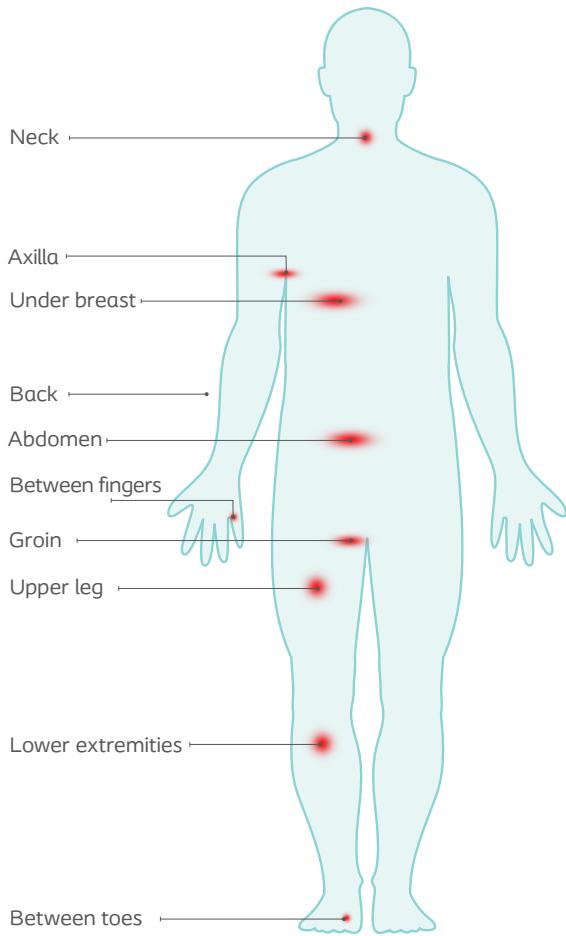
The moisture-wicking fabric was originally secured with paper tape. Removing the paper tape caused a medical adhesive-related skin injury. Next, the fabric was secured with silicone tape. Due to excessive moisture on the skin, the tape lifted. Returned to using paper tape in conjunction with an adhesive remover spray to help release the tape from the skin.

References

1. Gray M, Black JM, Baharestani MM, Bliss DZ, Colwell JC, Goldberg M, Kennedy-Evans KL, Logan S, Ratliff CR. Moisture-associated skin damage: overview and pathophysiology. *J Wound Ostomy Continence Nurs.* 2011;38(3):233-241
2. Sibbald RG, Kelley J, Kennedy-Evans KL, Labrecque C, Waters N. A practical approach to the prevention and management of intertrigo, or moisture-associated skin damage, due to perspiration: expert consensus on best practice. *Wound Care Canada - Supplement.* 2013;11(2):1-21
3. Black JM, Gray M, Bliss DZ, Kennedy-Evans KL, Logan S, Baharestani MM, Colwell JC, Goldberg M, Ratliff CR. MASD part 2: incontinence-associated dermatitis and intertriginous dermatitis: a consensus. *J Wound Ostomy Continence Nurs.* 2011;38(4):359-370
4. Edwards C, Cuddigan J, Black J. Identification of organisms colonized at site of intertriginous dermatitis in hospitalized patients. Poster presented at: 3rd World Union of Wound Healing Societies; June 4-8, 2008; Toronto, Canada
5. Kennedy-Evans KL, Viggiano B, Henn T, Smith D. Multi-site feasibility study using a new textile with silver for management of skin conditions located in skin folds. Poster presented at: 20th Annual Symposium on Advanced Wound Care; April 28 - May 1, 2007; Tampa, FL and 39th WOCN® Society Annual Conference; June 9-13, 2007; Salt Lake City, UT

Caring for skin folds

Application sites



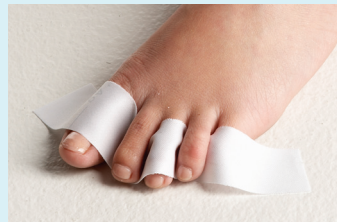SKIN-TO-SKIN



Under breasts

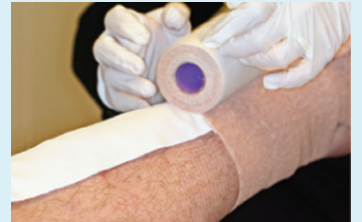

Abdomen

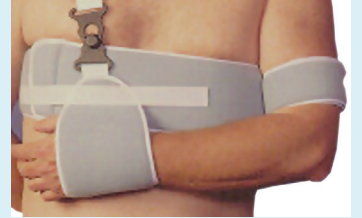

Between toes

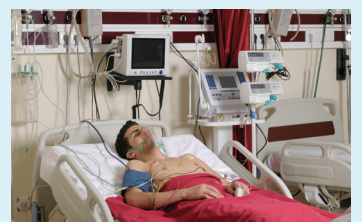SKIN-TO-DEVICE



Under braces, wraps or blood pressure cuffs



Under full immobilizers



Critical care settings

Treating complications associated with skin folds in a bariatric patient

Author: Rosemary Hill, BSN, RN, CWOCN, CETN(C)
Vancouver Coastal Health - Lions Gate Hospital, British Columbia, Canada

Introduction

A 66-year-old, 425 lbs. (193 kg) male with congestive heart failure (CHF), a history of COPD, obstructed sleep apnea, chronic left leg ulcer and morbid obesity was admitted to the hospital for CHF.

The WOC nurse was called to consult on a venous leg ulcer (VLU) and upon further assessment and dialogue with the patient, she conducted an assessment of all his skin folds. Her findings included erythema at the patient's chest skin fold (Figure 1).

The patient informed the WOC nurse that he had recently begun to experience extreme pain, itching and odor. The patient had unsuccessfully

tried to treat the area with creams that he found difficult to apply, expensive and took time to be effective.

Management of the skin fold

A moisture-wicking fabric with silver (InterDry® - Coloplast Canada Corp.) was applied in the skin folds on October 28 (Figure 2). On Day 7 (November 4) (Figure 3) there was no erythema or redness and the odor and discomfort had subsided.

The patient continued to use InterDry until discharge on Day 17 (November 14) when all symptoms of redness, itching and odor had been eliminated. The patient was also supplied with InterDry to continue using after discharge.

Conclusion

It is of paramount importance to complete a thorough assessment including skin folds when evaluating a high-risk bariatric patient. By Day 7, the moisture-wicking fabric with silver effectively reduced signs of inflammation, discomfort and odor. This is likely a result of the fabric's ability to wick away moisture, reduce skin-to-skin friction due to its polyurethane coating, and release ionic silver which further reduces microorganisms that cause odor.

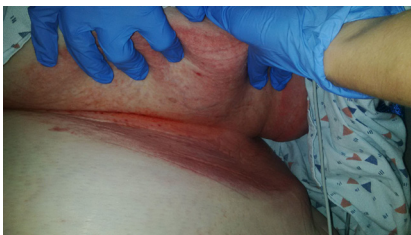

FIGURE 1
Patient complained of extreme pain, itching and odor. By now he had tried creams that he found to be difficult to apply and were minimally effective in reducing his symptoms.

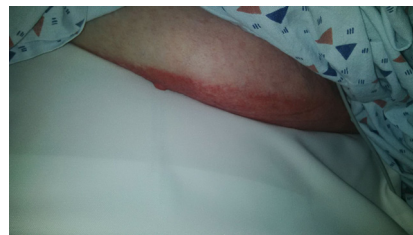

FIGURE 2
Moisture-wicking fabric with silver (InterDry – Coloplast Canada Corp) was applied on Day 1 by the WOC nurse with goals focused toward wicking excess moisture, reducing inflammation and in turn, reducing pain, itching, erythema, and eliminating odor-causing microorganisms.

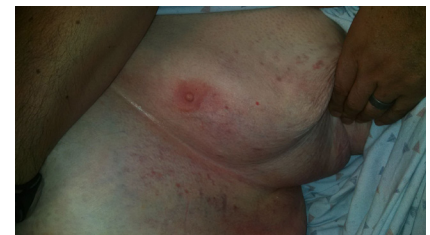

FIGURE 3
Day 7 after applying the moisture-wicking fabric with silver, the patient and caregiver noticed an almost complete elimination of symptoms.

Moisture management challenges for the WOC nurse

Authors: Julie Freyberg, BSN, RN, CWOCN; Debra Netsch, DNP, APRN, FNP-BC, CWOCN; Jan Tessling, MSN, RN, CWCN

Presented at the 39th WOCN® Society Annual Conference, June 2007

Presented at the 22nd Annual Clinical Symposium on Advances in Skin and Wound Care, October 2007

Sponsored by Coloplast

Introduction

Moisture management poses a particularly difficult challenge for the WOC nurse. Frequently, the WOC nurse is called when skin conditions arise from highly exudative venous stasis ulcers, excessive sweating (hyperhidrosis), intertrigo of deep skin folds, interdigital space maceration or periwound skin maceration resulting from draining wounds.

In our practice we have encountered denudement related to poorly managed moisture or failure of wounds to progress in the presence of copious drainage. Patients report comfort concerns related to burning, itching, and pain. Furthermore, secondary skin infections frequently occur following prolonged exposure to moisture in dark, warm environments such as under compression wraps, in deep skin folds, and in interdigital spaces. Traditional methods of moisture management are not always easy, reliable or successful. There are multiple treatment options available to achieve the goal of moisture management, and the decision-making tree is multifaceted in determining etiology and corresponding treatments. Products that address moisture control

through different mechanisms (e.g., absorption, wicking, and barriers) may lead to further complications. The problem is further complicated when treatment of secondary infections is necessary. There is often confusion in implementing treatment modalities and in educating the patient and/or caregivers. Therefore, a time-efficient, patient- and caregiver-friendly, cost-effective solution is sought.

Our desire for this research was to explore a single treatment option that eliminated the potential for product conflicts, and to simplify and streamline the treatment of skin conditions resulting from excessive skin hydration. Overall, the most important goal of this research was patient comfort and effective moisture management.

Objective

The objective of this case study series was to explore the use of InterDry®, combined with appropriate topical wound treatment and to manage skin conditions resulting from exposure to excessive moisture.

Method

This study was an open-label, non-randomized and non-comparative

case study evaluation of the clinical utility of InterDry. Patients were selected for inclusion based on the clinical judgment of the study investigators, and on the failure of previous methods of skin moisture and/or microbial control. All patients agreed to participate in the case study and signed consent for photography.

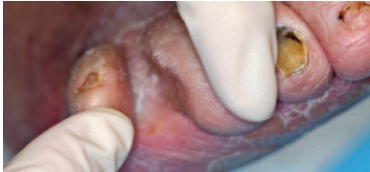
Conclusion

1. InterDry provided effective moisture management and microbial control in these four challenging clinical situations:
 - Intertrigo of interdigital spaces
 - Venous dermatitis complicated with hyperhidrosis
 - Maceration and malodor associated with skin occlusion by an external appliance.
 - Intertrigo of the axilla
2. InterDry was well received by both the patient and staff as it streamlined the process of moisture and microbial control into simple and easily implemented protocols of care.
3. Further research is warranted to develop additional protocols of care for moisture and microbial control using InterDry.

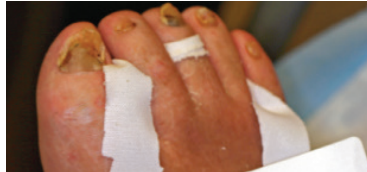Results

Case Study 1: A 69-year-old paraplegic male with severe peripheral arterial disease and known occlusion of the aortoiliac junction presented with maceration between his toes. Prior medical history included multiple back surgeries due to a benign spinal tumor and skin grafting resulting from radiation treatment approximately 50 years ago. Additional medical history included hypertension, dyslipidemia, non-insulin-dependent diabetes mellitus (NIDDM) type 2, venous insufficiency, diabetic neuropathic ulceration of the right foot, and venous insufficiency of the right lower extremity.

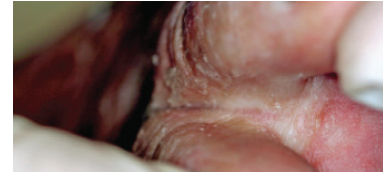
A one-inch strip of InterDry® was woven between his toes and changed daily following bathing. The maceration resolved within three days of treatment.



Maceration between toes before intervention



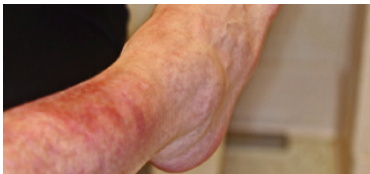InterDry between toes



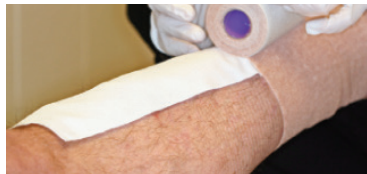Resolution of maceration within 72 hours

Case Study 2: A 42-year-old male presented with chronic, recurrent venous dermatitis to the lower extremities. Past medical history included Klinefelter's syndrome (KS), hypogonadism, NIDDM type 2, venous insufficiency, diabetic neuropathy, and mild mental retardation. Treatment of KS included testosterone injections, which caused excessive sweating. Compression wraps were used to treat the venous insufficiency ulcers, but this resulted in venous dermatitis and a new ulceration due to maceration caused by the excessive sweating.

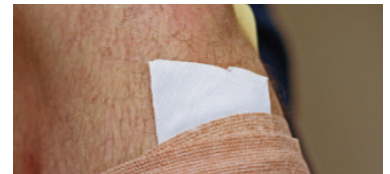InterDry was used under the compression wrap to wick away excessive moisture, resulting in elimination of the maceration and venous dermatitis.



Macerated venous dermatitis



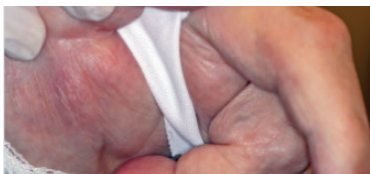Compression wrap over InterDry



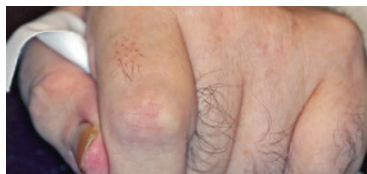Completed application

Case Study 3: A 66-year-old male presented with contracture of the left hand requiring the use of a brace. Previous medical history included CVA with left hemiplegia, heart failure, hypertension, hyperlipidemia, NIDDM type 2, history of acute DVT and coronary artery disease.

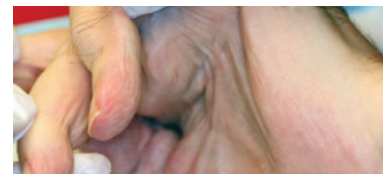The palm and interdigital spaces of the left hand frequently became macerated and malodorous, so he would stop using the brace. A two-inch strip of InterDry was placed in the palm of his hand and changed daily. This prevented maceration and malodor from occurring, allowing uninterrupted treatment with the brace. His hand was dry and comfortable, and he stated, "Whoever thought up this product was really smart! My hand has never felt this dry before."



Placement of InterDry



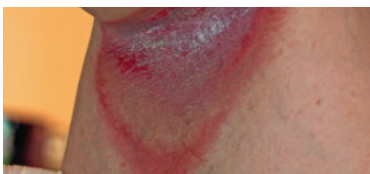InterDry fabric exposed to air



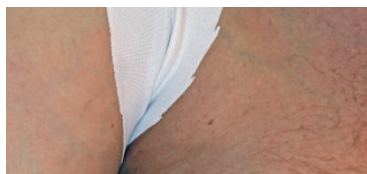Resolution of maceration under brace

Case Study 4: A 44-year-old male presented with intertrigo in his axilla, panniculus and groin folds. The patient had a history of alcoholism and was admitted for alcohol poisoning. Before the WOC nurse was consulted, the treatment was an antifungal-steroid cream combination. The affected areas were painful; and the moist desquamation and patient compliance with a new treatment was a concern.

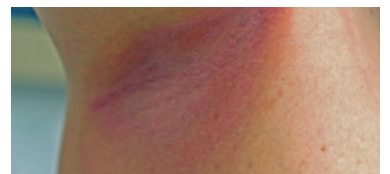Treatment was changed from the cream to InterDry. A silicone dressing with an adhesive spray (on intact skin) was used to secure the silver textile in place. Within 24 hours, the moist desquamation was significantly improved. After discharge, the patient modified the procedure, by securing the silver textile with surgical tape. Within one week, the affected areas were completely healed.



Intertrigo of the axilla before intervention



InterDry secured in place with spray adhesive



Resolution of intertrigo

Evaluation of a skin fold management textile with antimicrobial silver complex in a variety of case studies

Author: Ellen Vorbeck, DNP, APRN-BC, CWOCN, CWS
Mayo Health System, Minnesota, USA

Sponsored by Coloplast

Introduction

Intertrigo, a dermatitis that is often painful, results from moisture and friction in skin folds or juxtaposed skin areas. Intertrigo is difficult to treat and often results in complications, such as secondary bacterial or fungal infections and pressure ulcers. Clinicians often select treatments such as lotions, creams, powders, oral antifungal treatments, towels, pillowcases, baby blankets and absorbent briefs to control moisture and address the erythema and rashes associated with intertrigo. These measures are generally ineffective long-term solutions and may even

contribute to the development of pressure ulcers through the creation of new pressure points. Case studies are presented that demonstrate the effectiveness of InterDry[®], a skin fold management product that is a 100% polyester knitted textile with antimicrobial silver complex. It is designed to manage moisture, friction and odor.

Purpose

The objective of this case study series was to explore the use of InterDry to manage skin conditions resulting from exposure to excessive moisture in skin folds.

Methodology

This study was an open-label, non-randomized and non-comparative case study evaluation.

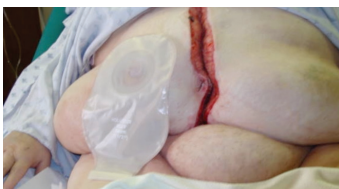Conclusion

InterDry provided effective moisture management and microbial control in four challenging clinical situations. The product was well received by both the patient and staff as it streamlined the process of moisture and microbial control into simple and easily implemented protocols of care.

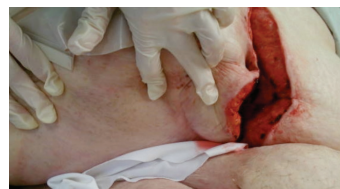Case Study 1: 71-year-old female patient, presented for surgical wound status post massive gastrointestinal bleeding and hemorrhagic shock. Subtotal colectomy with end ileostomy was performed to stop massive lower gastrointestinal bleeding. She subsequently developed a large seroma at the surgical incision which was opened and drained. The wound was then left open to the fascial layer to heal by secondary intention. Patient's past medical history included mechanical aortic valve replacement, anticoagulation therapy, atrial fibrillation, obesity, chronic obstructive pulmonary disease, and chronic renal insufficiency.

Skin Assessment: Negative pressure wound therapy (NPWT) was instituted; however, the large abdominal pannus trapped too much moisture resulting in intertrigo with erosions and erythema. This made adhesion of the drape impossible and was painful for the patient.

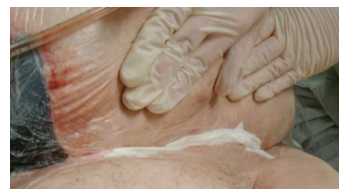Study Protocol: Two strips of InterDry were placed beneath the abdominal pannus fold; one on each side of the abdominal incision. The textile was replaced with each NPWT dressing change which allowed for adhesion of the NPWT drape. The patient's intertrigo was resolved with no subsequent intertrigo throughout the duration of the NPWT.



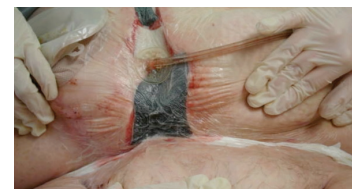Pannus and mons pubis prior to application of textile and NPWT drape.



Prior to application of NPWT drape, the textile was placed in the abdominal pannus fold. There was some initial absorption of wound drainage in the abdominal fold until the NPWT dressing was secured.



The NPWT drape was placed to allow 2 inches of the textile to be exposed for translocation and evaporation of perspiration in the pannus fold.

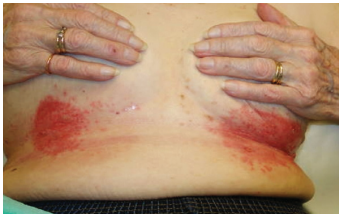

Demonstrates the technique used to eliminate friction and perspiration associated with intertrigo and assist in maintaining NPWT.

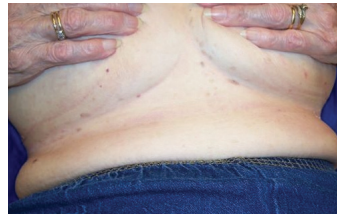Case Study 2: 92-year-old female patient presented for care of venous stasis ulceration complicated of a persistent, painful rash underneath her breasts that had been unresponsive to treatment with topical creams and powders. Patient's past medical history included chronic venous insufficiency, venous stasis ulceration, hypertension, and diabetes.

Skin Assessment: Candidal intertrigo with erythematous papules, satellite lesions, denudement, weeping and a musty odor. Past treatment included prescription antifungal powder applied twice daily and an oral antifungal administered daily for five days. The rash persisted and she was then treated with an antifungal cream applied two times daily for two weeks. The treatments were not effective.

Study Protocol: Two strips of InterDry® under each breast using a cotton sports bra to keep textile in place. The patient followed up weekly with improvement noted at Week 2 and resolution of symptoms and rash by Week 3.



Candidal intertrigo beneath both breasts at initial visit.

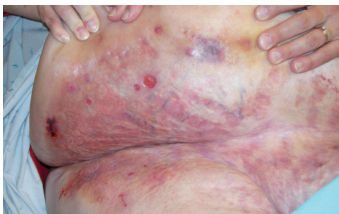

Week 3 resolution of candidal intertrigo beneath both breasts.

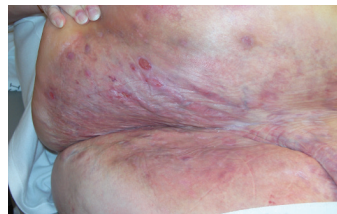
Case Study 3: 41-year-old female patient presented with non-healing ulcers and rash under her abdominal pannus. The patient was scheduled for bariatric surgery and at her preoperative physical was told she would not be able to proceed until her rash and ulcers were resolved. Patient's past medical history included morbid obesity, situs inversus totalis, diabetes, arthritis, hypertension, sleep apnea, and pseudotumor cerebri diverticulitis.

Skin Assessment: Candidal intertrigo with erythema, pain, cutaneous erosions with bleeding and a sweet odor. Cultures were completed and revealed mild *pseudomonas* infection and candidiasis. Past treatment included oral and topical antifungal treatment, paper towels, washcloths and baby diapers. The rash and symptoms never resolved.

Study Protocol: InterDry beneath the abdominal pannus. The patient followed up in one week with complete resolution of her candidal intertrigo and resolving erosions. The patient returned to the surgeon who scheduled her bariatric surgery.



Initial visit showing candidal intertrigo beneath the abdominal pannus with erosions and *pseudomonas* infection.

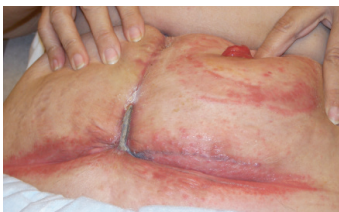

Week 1 follow-up visit showing resolution of candidal intertrigo and improving condition of erosions.

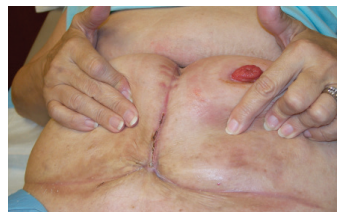Case Study 4: 67-year-old female patient presented for a follow-up after hospitalization for perforated sigmoid diverticuli with surgical intervention and subsequent diversion of fecal stream with end loop colostomy and Hartmann's pouch formation. She was experiencing a red rash that was painful and itching below her pouch and abdominal fold. Patient's past medical history included breast cancer, Bell's palsy, osteoporosis, depression, and dyslipidemia.

Skin Assessment: Candidal intertrigo underneath the abdominal pannus and colostomy pouch with satellite lesions, erythematous papules, denudement, weeping and a musty odor. Past treatment included an oral antifungal regime for 5 days in conjunction with an antifungal powder. She did have some improvement of symptoms under the colostomy-pouching surface but the intertrigo did not improve.

Study Protocol: InterDry under the abdominal pannus using cotton underwear to keep textile in place. The patient followed up in one week with marked improvement and at the fourteen-day follow-up the patient had complete resolution of the candidal intertrigo.



Candidal intertrigo beneath the abdominal pannus at initial visit.



Day 14 resolution of candidal intertrigo beneath the abdominal pannus.

Multi-site feasibility study using a new textile with silver for management of skin conditions located in skin folds

Authors: Karen Lou Kennedy-Evans, RN, FNP, APRN-BC; Barbara Viggiano, RN, WCC; Therese Henn, BSN, RNCS, ANP-BC, GNP-BC; Debra Smith, RN

Presented at the 20th Annual Symposium on Advanced Wound Care, April 2007

Presented at the 39th WOCN® Society Annual Conference, June 2007

Sponsored by Coloplast

Introduction

Intertrigo results from excess moisture and skin-to-skin friction occurring in natural skin folds, such as those found in the groin, abdomen, under breasts, legs, neck, and arms.¹ When intertrigo is left untreated, complications may result such as secondary bacterial or fungal infections.^{2,3} Standard treatments consisting of drying agents, barrier creams, topical antifungals, and absorptive materials are often ineffective.

Purpose

This feasibility study was designed to determine the efficacy of InterDry® used in place of the standard treatments.

Methodology

Subjects were enrolled from two (2) long-term care centers after signing the IRB approved consent form. Assessments occurred on Day 1, 3, and 5 for erythema, maceration, denudement, itching/burning, satellite lesions and odor. The amount of test product used was recorded.

Subjects

Twenty-one (21) subjects entered the study, with twenty (20) having complete data. Mean age 53.8 years. Mean BMI 54.75. Data was collected from each subject on Day 1 (Baseline), Day 3, and Day 5. Missing data was treated using the Last Observation Carry Forward (LOCF) technique. The Paired Sign Test was used for all analyses.

Conclusion

InterDry provided the environment to relieve the subjects' symptoms of intertrigo and/or candidal intertrigo in a five (5) day period. InterDry is an innovative product with impressive and dramatic results eliminating the need for multiple products that were ineffective. The subjects liked using the new product. They appreciated the comfort of not having moist skin and the absence of messy powders or creams on their skin.

References

1. Brown J, Wimpenny P, Maughan H. Skin problems in people with obesity. *Nurs. Stand.* 2004;18(35):38-42
2. Janniger CK, Schwartz RA, Szepietowski JC, Reich A. Intertrigo and common secondary skin infections. *Am Fam Physician.* 2005;72(5):833-838
3. O'Dell ML. Skin and wound infections: an overview. *Am Fam Physician.* 1998;57(10):2424-2432

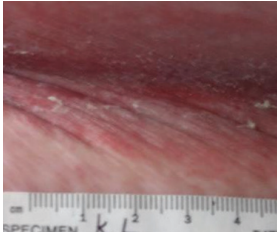
Product notations

- a. Silvadene®, Monarch Pharmaceuticals Inc. a subsidiary of Pfizer, Bristol, TN
- b. Mycolog II, Fougere Pharmaceuticals Inc., Melville, NY
- c. Nystop®, Paddock Laboratories, Inc., Minneapolis, MN
- d. Aloe Vesta®, ConvaTec, Bridgewater, NJ
- e. Aloe Vesta® 2 n 1 antifungal ointment, ConvaTec, Bridgewater, NJ
- f. Aloe Vesta® Lotion, ConvaTec, Bridgewater, NJ

Other products listed are registered trademarks of the respected company.

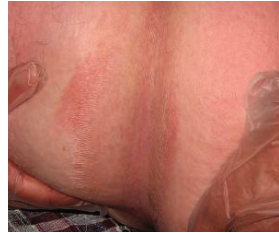Case Study 1: 46-year-old female receiving rehabilitation (physical therapy and weight loss) for morbid obesity (BMI 93.8). Other diagnoses include osteoarthritis, lupus, type II diabetes mellitus, and hypothyroidism. Skin assessment: candidal intertrigo located in the right posterior thigh, which has been present for the past 98 days. The current skin care protocol includes daily cleansing with Bedside-Care® Foam followed by an application of antimicrobial cream^a mixed equal parts with an antifungal cortisone^b cream daily and an antifungal powder^c as needed. She also has an order for an antifungal powder^c mixed equal parts with and antifungal cortisone^b cream.

Study Skin Care Protocol: Cleanse the skin with Bedside-Care Foam. Place InterDry® in the skin fold. Reposition as needed. Replace if soiled. Discard on Day 5.



Day 1
 Erythema score:
 3 - Severe
 Denudement: Yes
 Maceration: Yes
 Satellite lesions: Yes
 Itching/burning: Yes
 Odor score: 1 - Slight

Prior treatment cost
 Duration = 98 days
 Cost/week = \$23.84
 Total cost 14 weeks
 = **\$333.76**

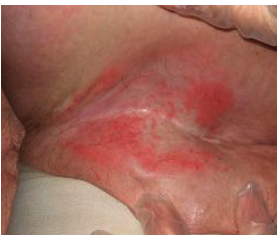

Day 5
 Erythema score:
 1 - Slight
 Denudement: No
 Maceration: No
 Satellite lesions: No
 Itching/burning: No
 Odor score: 0 - None

Day 5 - Resolved using 10" x 22" InterDry
 Duration = 5 days
 Total cost 5 days
 = **\$7.63**

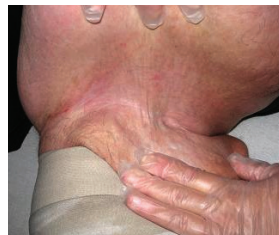Case Study 2: 34-year-old female receiving rehabilitation (weight loss and physical therapy) with morbid obesity (BMI 61.1). Other diagnoses include cellulitis bilateral lower extremities, chronic obstructive pulmonary disease, elephantiasis vs. lymphedema and chronic pain. Skin assessment: candidal intertrigo in the right popliteal area, which has been present for the past thirty-three (33) weeks. The current skin care protocol includes a daily body wash^d followed by an antifungal ointment^e as needed. She wore lower leg lymphedema wraps.

Study Skin Care Protocol: Cleanse the skin with Bedside-Care Foam. Place InterDry in the skin fold. Reposition as needed. Replace if soiled. Discard on Day 5.



Day 1
 Erythema score:
 3 - Severe
 Denudement: Yes
 Maceration: Yes
 Satellite lesions: Yes
 Itching/burning: Yes
 Odor score: 2 - Moderate

Prior treatment cost
 Duration = 231 days
 Cost/week = \$4.35
 Total cost 33 weeks
 = **\$143.55**

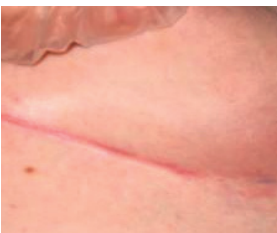

Day 5
 Erythema score:
 1 - Slight
 Denudement: Yes (Improving, skin is fragile and tears easily)
 Maceration: No
 Satellite lesions: No
 Itching/burning: No
 Odor score: 0 - None

Day 5 - Resolved using 10" x 24" InterDry
 Duration = 5 days
 Total cost 5 days
 = **\$8.33**

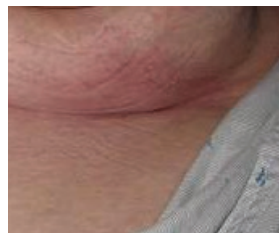Case Study 3: 53-year-old female with morbid obesity (BMI 62.8), angina, pulmonary embolism, venous insufficiency and bipolar disorder. She is unable to ambulate; a chair lift is used to position her in a wheelchair. Skin assessment: intertrigo under the left breast, which has been present for twelve (12) weeks. The current skin care protocol includes cleansing with a body wash^d followed by a lotion^f and an antifungal powder^e two times a day and as needed.

Study Skin Care Protocol: Cleanse the skin with Bedside-Care Foam. Place InterDry in the skin fold. Reposition as needed. Replace if soiled. Discard on Day 5.



Day 1
 Erythema Score:
 3 - Severe
 Denudement: Yes
 Maceration: Yes
 Satellite lesions: Yes
 Itching/burning: Yes
 Odor score: 1 - Minimal

Prior treatment cost
 Duration = 84 days
 Cost/week = \$8.68
 Total cost 12 weeks
 = **\$104.16**



Day 5
 Erythema Score:
 1 - Slight (dry flaking skin continues)
 Denudement: No
 Maceration: No
 Satellite lesions: No
 Itching/burning: No
 Odor score: 0 - None

Day 5 - Resolved using 10" x 8" InterDry
 Duration = 5 days
 Total cost 5 days
 = **\$2.77**

Coloplast develops products and services that make life easier for people with very personal and private medical conditions. Working closely with the people who use our products, we create solutions that are sensitive to their special needs. We call this intimate healthcare.

Our business includes ostomy care, continence care, wound and skin care and urology care. We operate globally and employ more than 10,000 employees.

Important Safety Information: InterDry[®] is a skin protectant for the management of skin folds and other skin-to-skin contact areas. It reduces microbial colonization in the fabric. This single use fabric provides moisture translocation to keep skin dry while the antimicrobial in the fabric reduces odor. The safe use of InterDry fabric during pregnancy, lactation and on children has not been demonstrated. Although many patients benefit from the use of this product, results may vary. Discuss the treatment options with your physician to understand the risks and benefits to determine if InterDry is right for you. For further questions, call Coloplast Corp at 1-800-533-0464 and/or consult the company website at www.coloplast.us.

Ostomy Care / Continence Care / Wound & Skin Care / Urology Care

Coloplast Corp. Minneapolis, MN 55411 / 1-800-533-0464

www.coloplast.us The Coloplast logo is a registered trademark of Coloplast A/S. © 2016 Coloplast Corp. All rights reserved.



M5096N 06.16